

Spontaneous Hemoperitoneum in Pregnancy (SHiP) due to endometriosis during pregnancy : A Case Report

So Hee Park¹, Jeong In Choi¹, Soo Ho Chung¹, Jae Hong Sang¹

Department of Obstetrics and Gynecology, Soonchunhyang University Bucheon Hospital

Introduction

Spontaneous Hemoperitoneum in Pregnancy (SHiP), a non-traumatic intraperitoneal bleeding in pregnancy, is associated with serious adverse pregnancy outcomes. Although the exact etiology of SHiP is still unknown, endometriosis is thought to be contributive factor in the occurrence and severity of SHiP. Traditionally, pregnancy was known to have a positive effect on endometriosis but it had been recently revealed that decidualization during pregnancy can cause increased size of endometriomas and deep infiltrative endometriosis implants.

Case report

We report a case of 38-year-old Primipara twin pregnancy, which was accomplished by IVF. The patient was hospitalized for conservative treatment on preterm labor. At 29+4weeks gestation, she complained sudden abdominal pain without contraction detected on nonstress test. There was no vaginal bleeding but ultrasonography demonstrated intraperitoneal fluid collection. Immediate emergency Cesarean section was operated under diagnosis of SHiP. After twins were out, operator found torn endometriosis spot on posterior side of maternal uterus with active bleeding, which was the cause of sudden abdominal pain and hemoperitoneum.

Conclusion

The major symptoms of SHiP are acute abdominal pain, followed by hypovolemic shock and fetal distress. Ultrasound examination may or may not present intraabdominal fluid collection. Also SHiP is not a common cause of abdominal pain in pregnancy, since preventive measures and evidence-based intervention other than laparotomy are currently not available, increasing the awareness and recognition of SHiP is important to further improve pregnancy outcomes.

Also in this case, it is highly probable that unknown cause of infertility that eventually led to IVF was endometriosis. If the possibility of SHiP is taken into consideration when approaching abdominal pain especially in pregnancy with ART, it would be a great help in appropriate treatment.

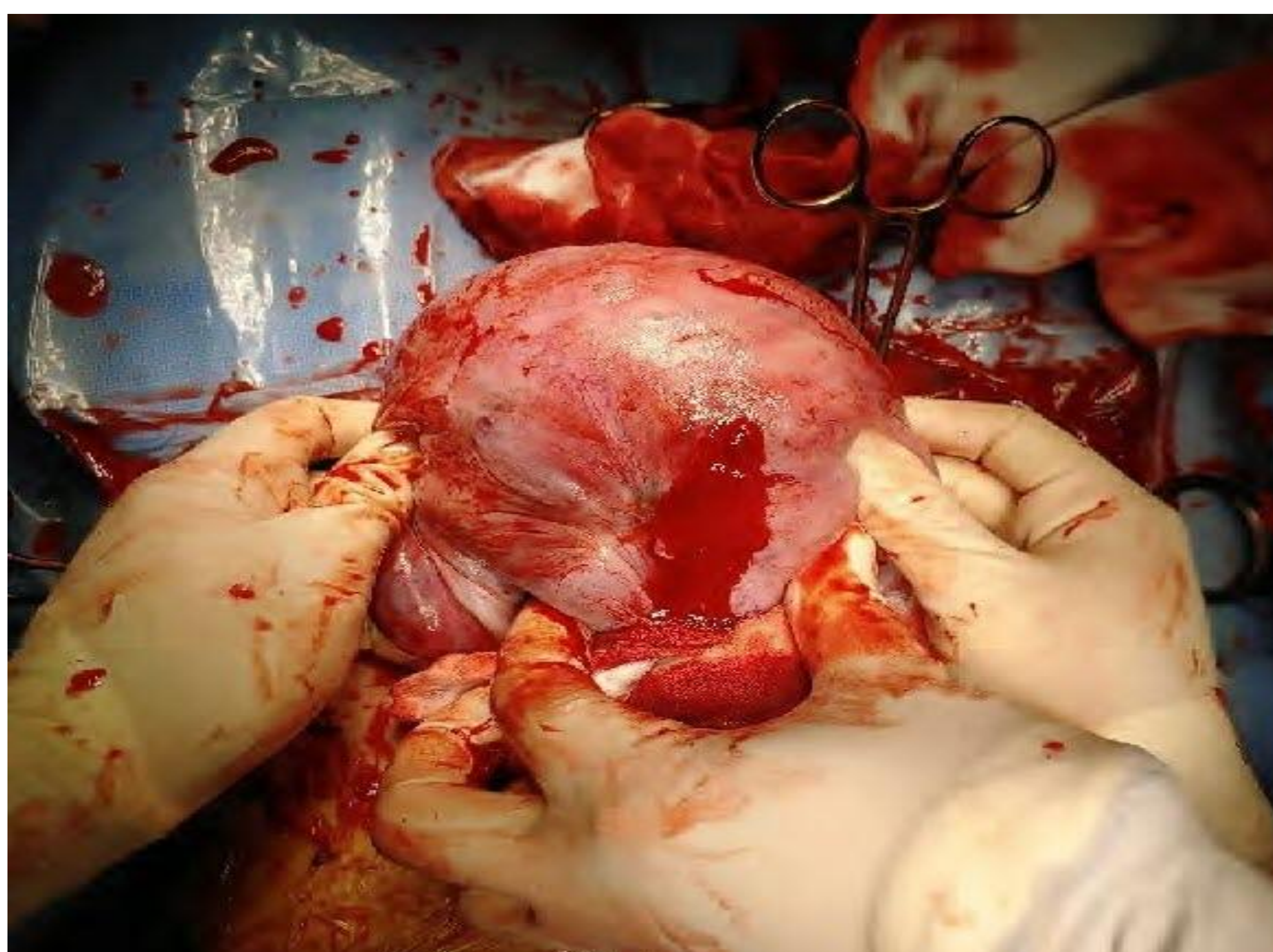


Figure. Torn endometriosis spot with active bleeding on uterus